DIGESTION & ABSORPTION

DIGESTION

- The breakdown of complex food into simplest form is called Digestion.
- Enzymatic hydrolysis of complex food into its simplest form at a specific pH value is called Digestion.

TYPES

- Intracellular Digestion
- Intercellular Digestion
- Mechanical Digestion
- Chemical Digestion

STRUCTURE

BUCCO-PHARYNGEAL CAVITY

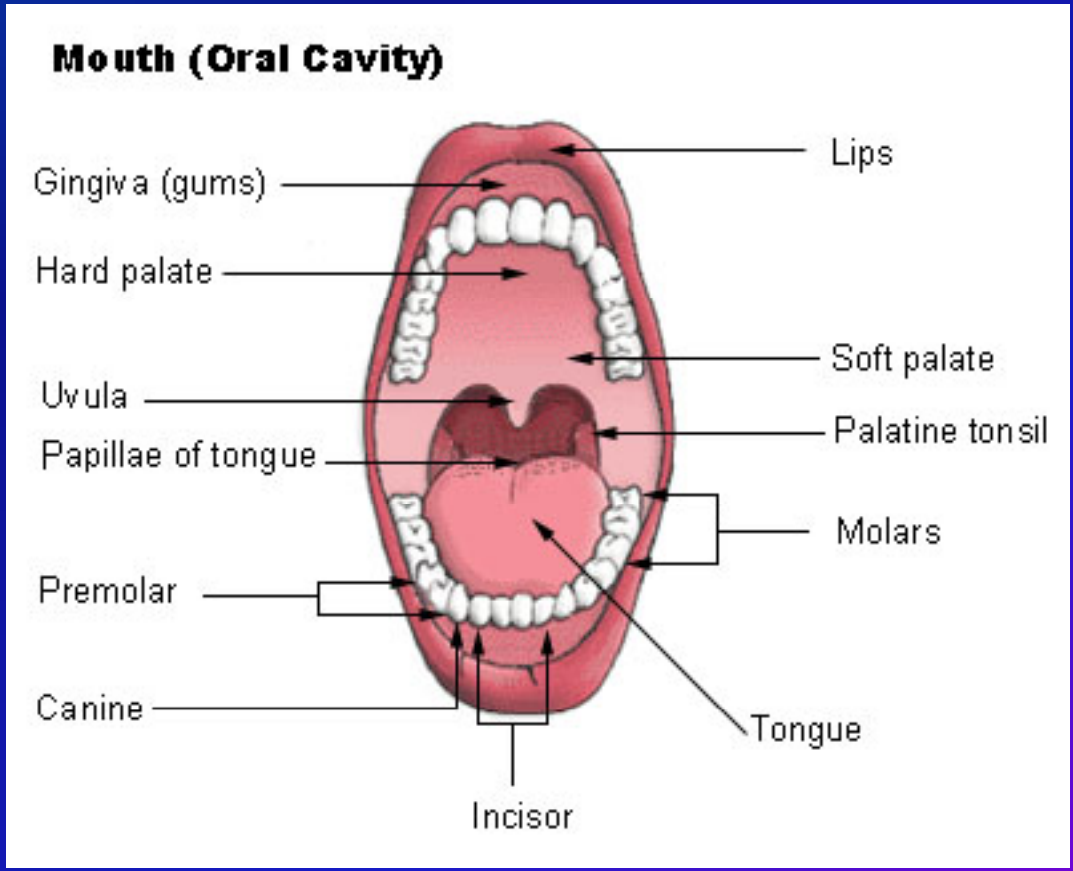

GASTRO-INTESTINAL TRACT OR ALIMENTARY CANAL

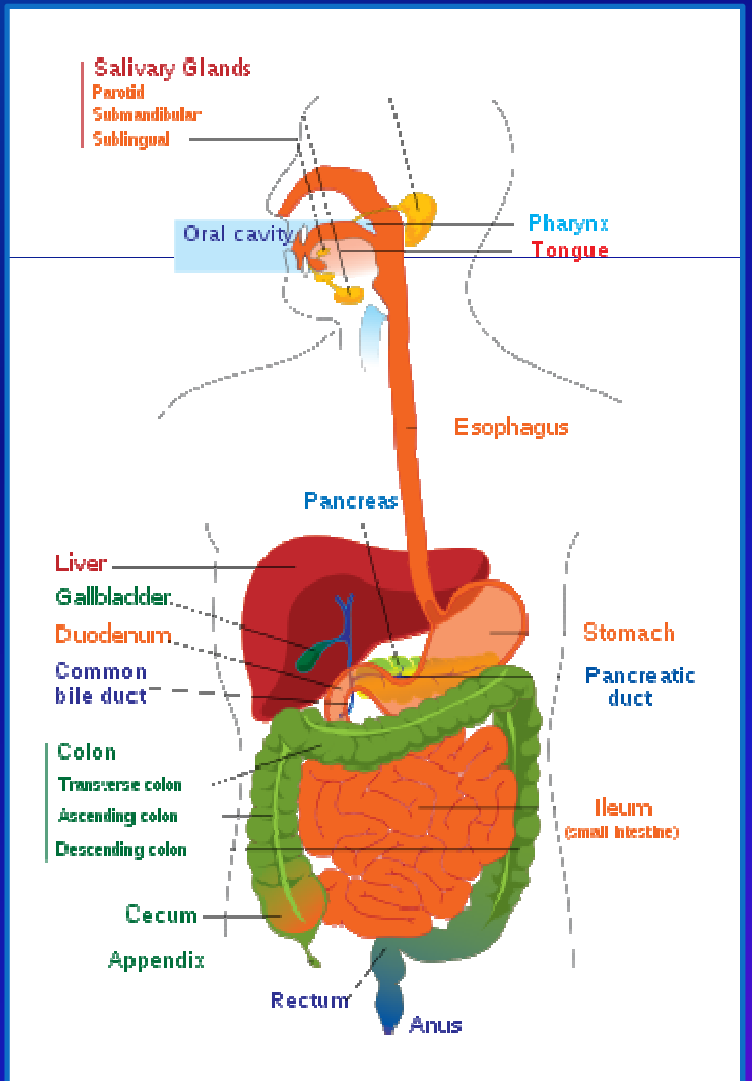

ANATOMY OF ALIMENTARY CANAL

- Serosa
- Muscularis
- Sub-Mucosa
- Mucosa
  - Villi
  - Blood capillaries
  - Lacteoles
  - Glands
  - Lamina Propria

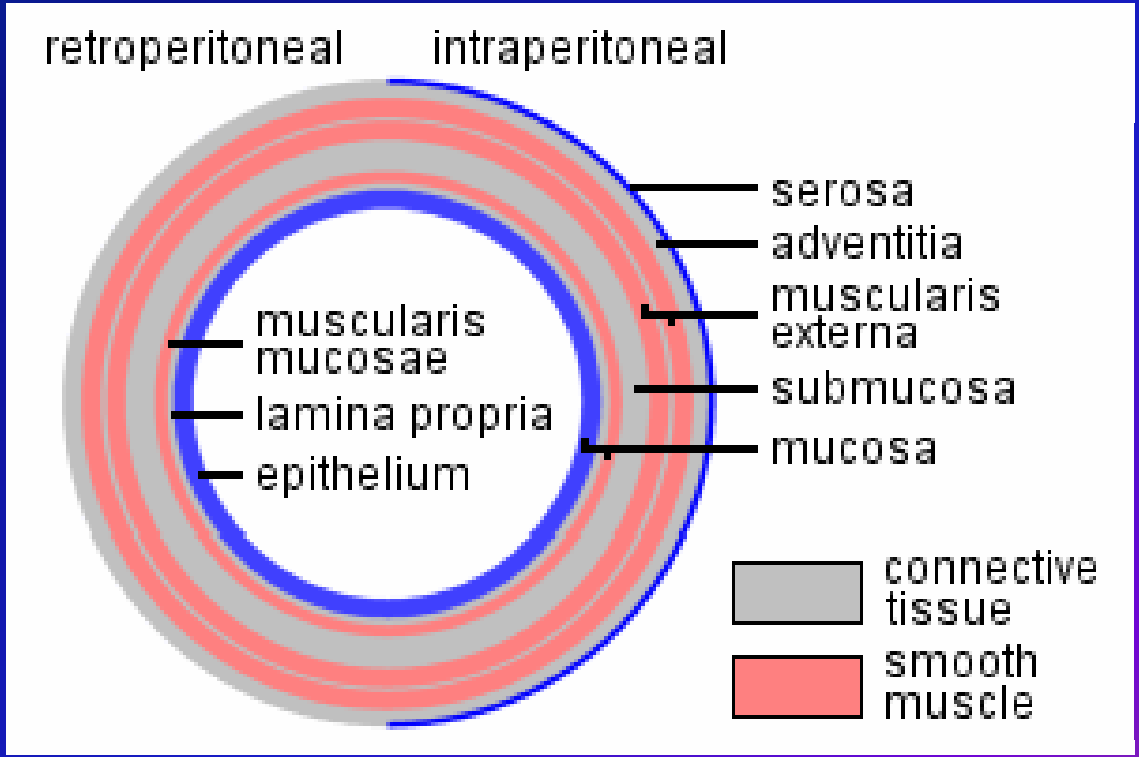

ACCESSORY DIGESTIVE ORGANS

- **Salivary Glands:** They are exocrinal glands found within the buccal cavity at different sites. They are paired structures.

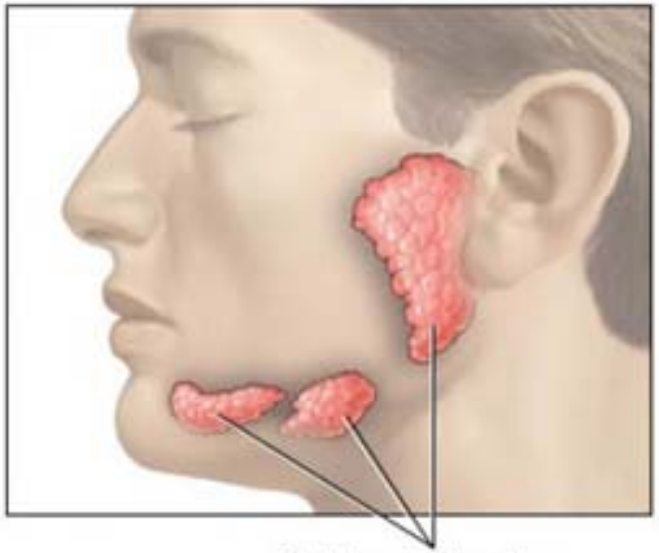

They are of Three types namely:

a)**Parotid glands:** found just below the ear lobe or within the cheek.

b)**Sub-mandibular/Sub-maxillary glands:** found below the lower jaw.

c)**Sub-lingual glands:** found below the tongue.

LIVER & PANCREAS

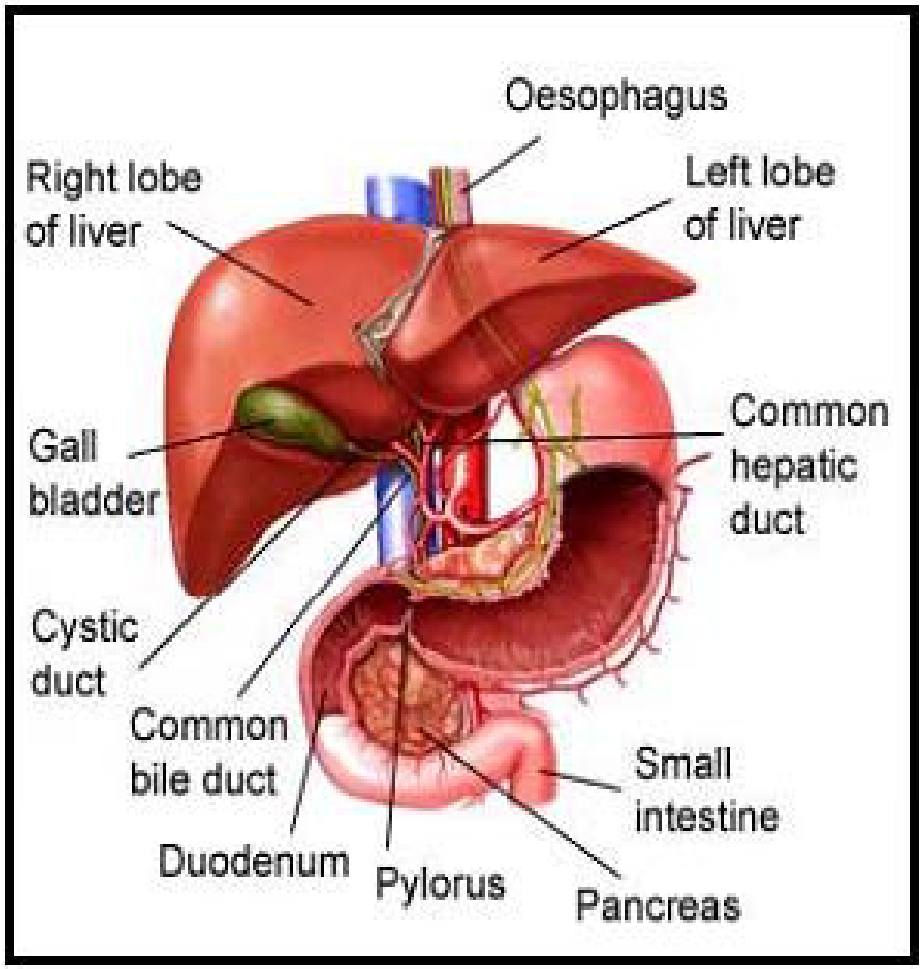

- **LIVER:** It is the largest exocrine gland found in man. It is five lobed It has four complete lobes and one incomplete lobe. They extend hepatic ducts. Just behind the third lobe it has Gall bladder which extends cystic duct. Both of them fuse to form Bile duct.

  It secretes Bile; helps in digestion of fats.

- **PANCREAS:** It is an irregular multilobular yellow coloured dual gland found within the loop of duodenum. It has exocrinal units called Acini, which secrete pancreatic juice helps in digestion of carbohydrates, proteins and lipids. It ha endocrinal units called Islets of langerhans which secrete Glucagon, Insulin and somatostatin which regulate carbohydrate metabolism.

PHYSIOLOGY OF DIGESTION

Digestion in Bucco-pharyngeal cavity:

- Ingestion
- Retention
- Mastication
- Insalivation
- Partial hydrolysis
- Formation of bolus
- Swallowing
- Peristalisis

Digestion in Stomach:

- Role of HCl
- Role of Pepsin
- Role of Renin
- Chyme
- Role of Pyloric Sphinctors

Digestion in Small intestine:

- **Digestion of Proteins**
  - Role of Trypsin
  - Role of Chymo-trypsin
  - Role of Carboxy-peptidase
  - Role of Amino-peptides
  - Role of Erepsin

- **Digestion of Carbohydrates**
  - Role of Amylopsin
  - Role of Maltase
  - Role of Sucrase/Invertase
  - Role of Lactase

- **Digestion of Lipids:**
  - Emulsification
  - Role of Steapsin
  - Role of Intestinal Lipase

- **Chyle:**
  - Role of Villi
  - Role of Colon
  - Role of Rectum

ROLE OF APPENDIX

- Cicum
- Vermiform appendix
- Role of appendix

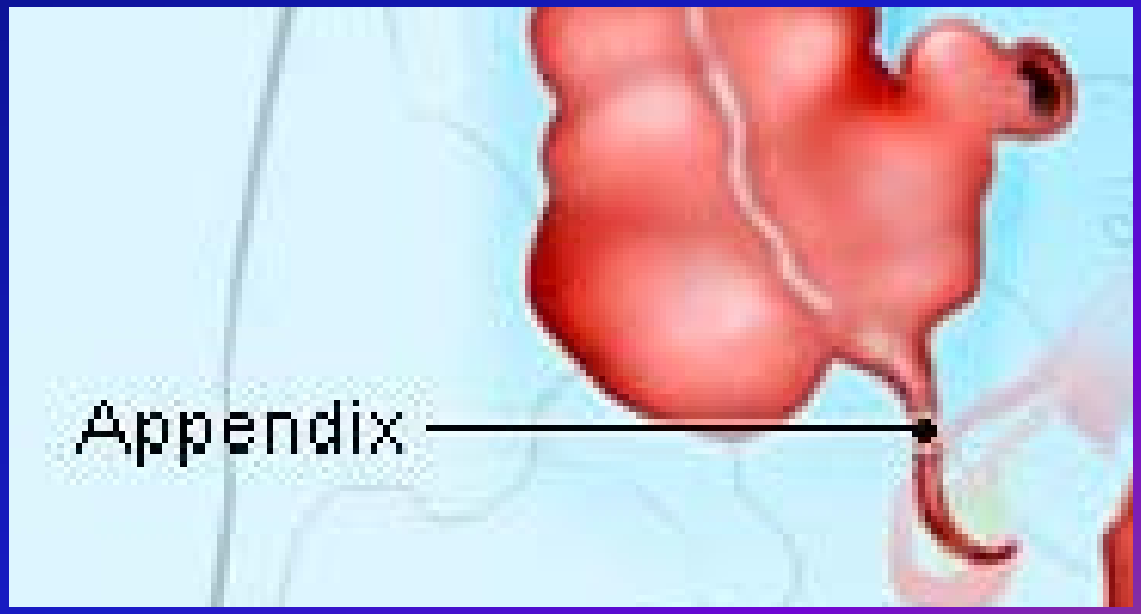

ABSORPTION

- Definition
- Structure of villus
- Mechanism of absorption

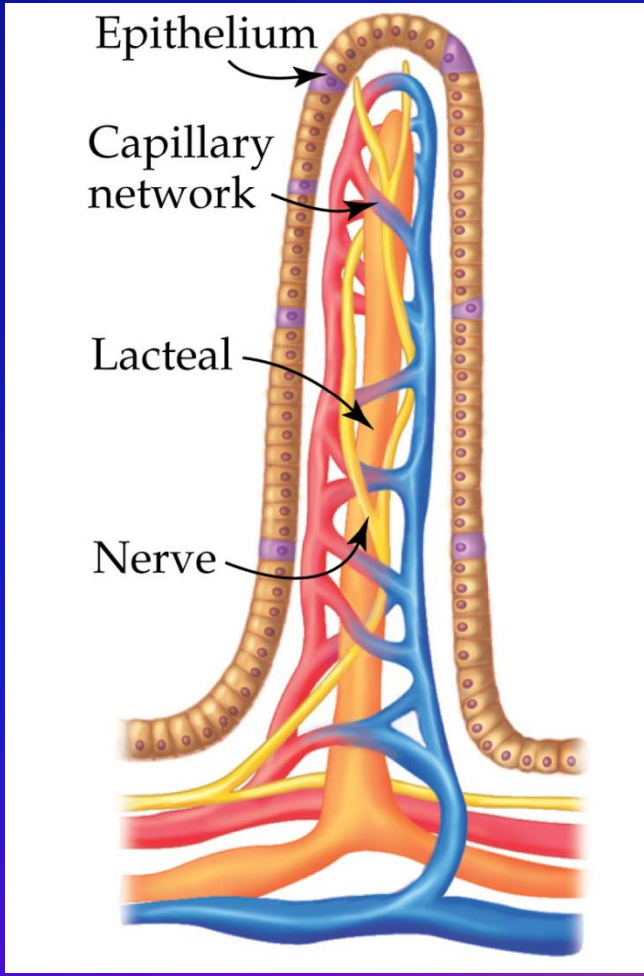

DIGESTIVE DISORDERS

- **Jaundice:** The liver is affected, skin and eyes turn yellow due to the deposit of bile pigments.

- **Vomiting:** It is the ejection of stomach contents through the mouth. This reflex action is controlled by the vomit centre in the medulla. A feeling of nausea precedes vomiting.

- **Diarrhoea:** The abnormal frequency of bowel movement and increased liquidity of the faceal discharge is known as diarrhoea. It reduces the absorption of food.
- **Constipation:** In constipation, the faeces are related within the rectum as the bowel movements occur irregularly.
- **Indigestion:** In this condition, the food is not properly digested leading to a feeling of fullness. The causes of indigestion are inadequate enzyme secretion, anxiety, food poisoning, over eating and spicy food.


Thank You